

Literature


Misch CF: *Contemporary Implant Dentistry* (2004)

Palti A, Steigmann M: *Long-term Success with Sinus Elevation – Criteria and parameters. International Magazine of Oral Implantology* (2003), pp20-24

Tatum H jr.: *Maxillary and sinus implant reconstructions. Dental Clinics of North America* 30 (1986), pp207-229

Palti A, Hermann F: *Die geschlossene Sinusbodenelevation. Eine retrospektiv-röntgenologische Studie auf der Basis von 204 Implantaten zur Beurteilung der erzielten Augmentationshöhe. Z Oral Implant* (2005) 1/05:16-14

We thank Dr. Ady Palti for the permission to use his photographs.



Step by Step Instruction for the Use of Cerasorb® and Epi-Guide® in Sinus Floor Elevation

The loss of posterior teeth of the maxilla in most cases leads to reduced bone mass since the lack of physiological load eventually results in an atrophy of the alveolar crest as well as the pneumatization of the sinus maxillaris. The remaining bone height is often insufficient for the placement of implants.

In the past surgeons/implantologists avoided the area of the maxillary sinus considering it an anatomic trap and, instead, implanted in front of or behind the maxillary sinus.

Meanwhile, the onlay of bone and/or bone regeneration material in the maxillary sinus floor region (sinus lift / sinus floor elevation) has proven to be a surgical procedure that successfully produces a sufficiently stable implant bed (Tatum H jr, 1986). To this day, two main surgical techniques are followed: The so-called internal (closed) and the external (open) sinus floor elevation. During the internal sinus lift, the mucosa is raised after accessing via the alveolar ridge in order to insert bone regeneration material. This is followed by the placement of the implants. If the maxillary sinus is entered via a lateral fenestration to bring in the graft material, we speak of an open sinus lift.

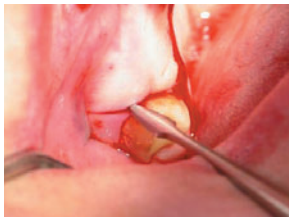In accordance with the classification of bone height by Misch (Misch CF, 1993), Palti suggests the following methods depending on the remaining bone height (Palti A, 2003):

- a) In case of a remaining bone height of 6-10 mm, a closed sinus lift is to be performed.
- b) If the remaining bone height is in the area of 4-6 mm, the open method with a lateral fenestration should be chosen in order to lift the Schneiderian membrane and insert the required quantity of bone regeneration material.
- c) If the remaining bone has a height of less than 4 mm, a two-step procedure is indicated. Here it is the aim – by way of an open sinus floor elevation – to insert enough bone regeneration material in the first step, and to place the implant in a second step 4-6 months later.

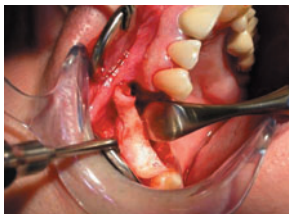Regardless of the technique used, the surgeon must have knowledge of the clinical and radiological diagnostics of acute and chronic diseases of the maxillary sinus. In cases with uncertain findings, an oral and maxillofacial surgeon or an otolaryngologist should be included in the assessment of the case. A pre-operative orthopantomogram is the minimum requirement for the pre-operative radiological diagnostics.

The following is the recommended course of action for an open sinus lift. It represents an exemplary demonstration of a two-step procedure (implantation approx. 4-6 months after the augmentation).

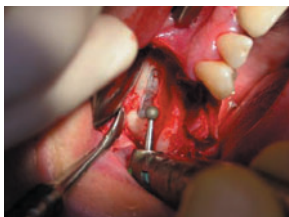
The recommended procedure of an open sinus floor elevation



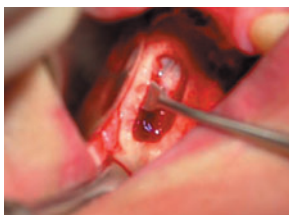After pre-operative routine preparations, a crestal incision and a vertical relief-incision in the tuber and canine regions are performed and a mucoperiost flap is detached.



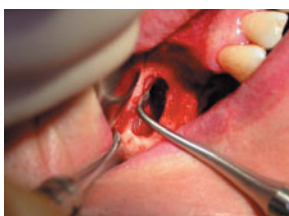Access to the maxillary sinus should be made approx. 2 – 3 mm below the sinus floor.



Next, a bone window is prepared in the premolar region. The preparation is performed with a larger size diamond rose burr under sufficient cooling (approx. 2000 r/pm).



Careful detachment of the Schneiderian membrane, basal, medial, cranial and dorsal, with a special set of instruments (e.g. sinus elevator).



Once the Schneiderian membrane has been lifted from the inner bone surface, the bony lid is moved in the cranial direction.

The use of membranes

The use of membranes in augmentation or implantological procedures is indicated if the periost is no longer intact (preferably resorbable membranes) or when it can be expected that a saliva-proof closure of the defect over the entire healing phase (3 – 9 months) can only be achieved through complex gingival surgery (a non-resorbable membrane is recommended).

The polylactide-based Epi-Guide® is a bio-resorbable membrane especially proven for sinus floor elevations. Its special structure facilitates the ingrowth of fibroblasts, while at the same time preventing the transgression of soft tissue. The barrier function of Epi-Guide® is maintained over more than six weeks, and complete resorption takes place within six to twelve months.

Preparation of the membrane

A particular cutting technique allows the membrane to be used both as protection for the Schneiderian membrane and as closure for the bone window. To achieve this, two wedges are cut from the Epi-Guide® membrane. The first triangle cut is made at approx. two thirds of the length of the membrane and should end at one third of the width. An identical triangle is cut exactly opposite.

After that, the trimmed Epi-Guide® membrane is held with tweezers, bent to a round shape and its larger part inserted into the maxillary sinus.

The cavity between the sinus floor and the sinus mucosa/membrane is filled with Cerasorb® or Cerasorb® M of a suitable size (e.g. 500-1000µm or 1000-2000µm) which has been mixed with blood from the defect. Optionally, PRP (platelet rich plasma) may be added after the admixing fresh blood from the defect.

The bone regeneration material should be inserted loosely (e.g. with a material scoop or applicator). The porous structure must not be destroyed by packing/excessive pressure.

Once the cavity has been filled completely, the bone window is closed with the overlapping part of the membrane.

Afterwards the site is closed with tension-free suture (horizontal mattress suture) and remains saliva-proof. In addition, a horizontal incision and suture may be required to relieve the periost.

